



## DISEASE IN WILDLIFE OR EXOTIC SPECIES

# Dental and Temporomandibular Joint Pathology of the Walrus (*Odobenus rosmarus*)

J. N. Winer<sup>\*</sup>, B. Arzi<sup>†</sup>, D. M. Leale<sup>†</sup>, P. H. Kass<sup>‡</sup> and F. J. M. Verstraete<sup>†</sup>

<sup>\*</sup> William R. Pritchard Veterinary Medical Teaching Hospital, <sup>†</sup> Department of Surgical and Radiological Sciences and <sup>‡</sup> Department of Population Health and Reproduction, School of Veterinary Medicine, University of California, Davis, CA, USA

## Summary

Maxillae and/or mandibles from 76 walruses (*Odobenus rosmarus*) were examined macroscopically according to predefined criteria. The museum specimens were acquired between 1932 and 2014. Forty-five specimens (59.2%) were from male animals, 29 (38.2%) from female animals and two (2.6%) from animals of unknown sex, with 58 adults (76.3%) and 18 young adults (23.7%) included in this study. The number of teeth available for examination was 830 (33.6%); 18.5% of teeth were absent artefactually, 3.3% were deemed to be absent due to acquired tooth loss and 44.5% were absent congenitally. The theoretical complete dental formula was confirmed to be I 3/3, C 1/1, P 4/3, M 2/2, while the most probable dental formula is I 1/0, C 1/1, P 3/3, M 0/0; none of the specimens in this study possessed a full complement of theoretically possible teeth. The majority of teeth were normal in morphology; only five teeth (0.6% of available teeth) were malformed. Only one tooth had an aberrant number of roots and only one supernumerary tooth was encountered. No persistent deciduous teeth were found in any of the young adult or adult specimens, nor were any specimens affected by enamel hypoplasia. The majority of teeth (85.5%) displayed attrition/abrasion. Of the adult and young adult specimens, 90.8% showed some degree of attrition/abrasion on at least one tooth. Tooth fractures were noted in eight walruses, affecting 10.5% of specimens and 1.3% of the total number of teeth, nearly three-quarters of which were maxillary canine teeth (tusks). Three specimens (3.9%), all adult males, displayed overt periapical disease. The majority (99.2%) of dental alveoli did not have bony changes indicative of periodontitis, with only five specimens (6.6%) affected by periodontitis. Lesions consistent with temporomandibular joint osteoarthritis (TMJ-OA) were found in 46 specimens (60.5%) and TMJ-OA was significantly more common in adults than young adults and males than females. Although the clinical significance of dental and TMJ pathology in the walrus remains unknown, the occurrence and severity of these lesions may play an important role in the morbidity and mortality of this species.

© 2016 Elsevier Ltd. All rights reserved.

**Keywords:** dental formula; dental pathology; temporomandibular joint pathology; walrus

## Introduction

The walrus (*Odobenus rosmarus*) is the sole extant species in the family Odobenidae, genus *Odobenus*, with three subspecies: *O. rosmarus* (the Atlantic walrus), *O. rosmarus divergens* (the Pacific walrus) and *O. rosmarus laptevi* (inhabiting the Laptev Sea of the Arctic Ocean). Walruses are distributed across the North

Pole, in the Arctic Ocean and subarctic seas, in a discontinuous range. They are a social species, living in groups occupying shallow waters, spending large amounts of time on sea ice. Walruses live up to 30 years in the wild (Fay, 1955). The Pacific walrus demonstrates pronounced sexual dimorphism (Fay, 1982). Adult males have a mean body length of 320 cm and an average body weight of 1,200 kg, while adult females have a mean body length of 272 cm and

Correspondence to: F. J. M. Verstraete (e-mail: [fjverstraete@ucdavis.edu](mailto:fjverstraete@ucdavis.edu)).

0021-9975/\$ - see front matter  
<http://dx.doi.org/10.1016/j.jcpa.2016.07.005>

© 2016 Elsevier Ltd. All rights reserved.

an average body weight of 800 kg (Fay, 1982). Among pinnipeds, walrus are only exceeded in size by the elephant seals (*Mirounga leonina* and *Mirounga angustirostris*).

The majority of walrus prey is located on the ocean floor, on or just beneath the surface of the sediment, at a depth of less than 100 m (Fay, 1982; Fay and Burns, 1988). The walrus locates its prey with its vibrissae and then uncovers it with its snout (Fay, 1982). Analysis of fresh stomach contents revealed that walrus consume a diverse diet, comprised of 100 taxa from 11 phyla (Sheffield *et al.*, 2001; Sheffield and Grebmeier, 2009). Walrus rarely ingest large non-benthic organisms such as fish, birds and seals (Freuchen, 1935; Vibe, 1950; Fay, 1982; Lowry and Fay, 1984; Gjertz, 1990; Donaldson *et al.*, 1995), but typically walrus utilize suction to remove molluscan prey from their shells (Vibe, 1950; Fay, 1982). The soft bodies are then swallowed whole, with no indication of mastication (Fay, 1982).

In order to counteract the buoyancy of its immense blubber and better swim to the benthic floor to forage, the walrus skeleton and skull, in particular, are pachyostotic. This non-pathological increase in skeletal mass and density is considered to play the functional role of ballast for buoyancy control (Ricqlès and Buffrénil, 2001; Houssaye, 2009).

Walrus dentition is variable, and the dental formula is represented inconsistently throughout the literature (Kryukova, 2012). Recently it has been reported as I 1/0, C 1/1, PC (postcanines) 3/3 (Jefferson *et al.*, 2008) and also as I 1-2/0, C 1/1, PC 3-5/3-4 (Hillson, 2005). The term ‘postcanine’ is occasionally used in marine mammalogy to denote the premolar and molar teeth. Fay (1982) amalgamated the results of previous studies and supplemented that data with his findings on the Pacific walrus after having examined 136 maxillae and 129 mandibles. He concluded that walrus may have between 18 and 38 teeth, representing the adult dental formula as follows: I (1)-(2)-3/(1)-(2)-(3), C 1/1, P 1-2-3-(4)/2-3-4, M (1)-(2)/(1)-(2). The teeth listed in parentheses were present in <50% of his adult specimens (i.e. the maxillary third incisor tooth is present consistently, while the mandibular first to third incisor teeth are present in <50% of adult specimens). Thus, the walrus is the pinniped species with the greatest number of potential teeth, but the least number occurring with greater than 50% probability (Fay, 1982) (Fig. 1).

The most striking dental feature of the walrus is its maxillary canine teeth, referred to as ‘tusks’ because of their marked elongation and exposure. The tusks erupt and lengthen continually, with males having tusks exceeding 1 m in length and females having

tusks up to 80 cm in length (Fay, 1982). Apart from the tusks, walrus dentition is made up of single-rooted peg-like teeth, which measure 2.5–5.5 cm in length and 1.0–2.5 cm in diameter when fully formed (Fay, 1982). The incisor teeth (except for the maxillary third incisor tooth) and molar teeth are vestigial and typically resorb prior to adulthood (Fay, 1982). Walrus occlusion is consistent with other carnivores in that it is anisognathous, the mandibles being narrower than the maxillae.

Their remote location and fragmented distribution make quantifying the total walrus population challenging (Speckman *et al.*, 2011). The Pacific walrus population was severely depleted in the late 19th century and in the mid-20th century by commercial hunting, but rebounded when harvests were reduced (Fay, 1982). More recently, predation, intraspecific trauma and microbial infections were reported as principal causes of mortality (Fay, 1982). With the ever-increasing threat of global climate change, loss of sea ice habitat is again threatening the walrus population (Jay *et al.*, 2011). Dental and temporomandibular joint (TMJ) lesions, which are common in certain wildlife species, may be important contributors to morbidity and mortality (Verstraete *et al.*, 1996a,b).

A series of papers has been published on dental and TMJ pathology of marine mammal species: the northern elephant seal (*M. angustirostris*) (Abbott and Verstraete, 2005), the southern sea otter (*Enhydra lutris nereis*) (Arzi *et al.*, 2013a; Winer *et al.*, 2013), the California sea lion (*Zalophus californianus*) (Sinai *et al.*, 2014; Arzi *et al.*, 2015), the northern fur seal (*Callorhinus ursinus*) (Aalderink *et al.*, 2015a) and the eastern Pacific harbour seal (*Phoca vitulina richardii*) (Aalderink *et al.*, 2015b). In general, museum collections of skulls, such as those making up the aforementioned studies and this study, are obtained from strandings, carcass recovery and donations by rehabilitation centres. Specific to Alaska, museum specimens are additionally sourced from permitted hunting for subsistence purposes and wildlife deaths as a result of ‘Defence of Life and Property’ laws. Pathological conditions are likely overrepresented in stranded animals as compared with the general population (Cowan, 2002); high numbers of stranded animals may be considered sentinels of emerging diseases (Gulland, 1999). The number of walrus skulls in museum collections is low, as the tusks are highly valued by native people, who are allowed to harvest them. The aim of this study was to determine the nature and prevalence of dental and TMJ pathology in the walrus by examining museum specimen skulls.

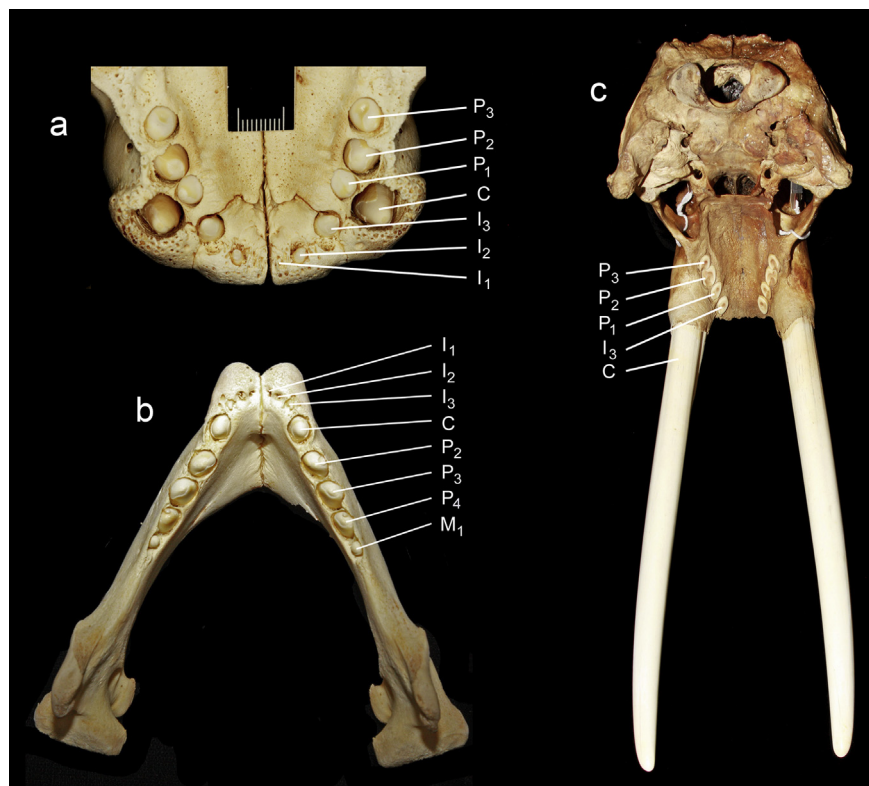


Fig. 1. Representative dentition of the walrus. (a) Maxilla of a juvenile specimen. (b) Mandible of a juvenile specimen. (c) Maxilla of an adult specimen. Bar, 1 cm.

### Materials and Methods

Macroscopic examination of 107 maxillae and/or mandibles from the Department of Mammalogy, Museum of the North, University of Alaska, Fairbanks, Alaska, was performed. Each specimen had been labelled previously with a unique catalogue number and the specimen's sex, collection location and collection date. 'Adult' versus 'young adult' categorization was determined by prominence of cranial sutures; 'juvenile' ageing was based on the presence of physiological deciduous or mixed dentition, which disqualified further study of these specimens (Winer *et al.*, 2013), leaving 76 specimens.

The teeth present, surrounding bone and the TMJs were inspected systematically according to predefined criteria (Table 1) utilized in former studies (Abbott and Verstraete, 2005; Winer *et al.*, 2013; Sinai *et al.*, 2014; Aalderink *et al.*, 2015a,b). Care was taken to rule out post-mortem trauma or preparation artefacts such as hairline cracks or artefactual sharp-edged fractures, potentially due to excessive heating and drying during skull preparation.

The presence or absence (i.e. congenital, acquired or artefactual) of all teeth was recorded. Missing teeth were taken into account when calculating the prevalence of abnormally formed teeth, attrition/abrasion,

dental fractures and enamel hypoplasia; a full complement of teeth was assumed when calculating prevalence of supernumerary teeth, bony changes consistent with periodontitis and periapical lesions.

Teeth were assessed for normal or abnormal form. The number of roots was determined primarily by assessing the visible part of the coronal root, as the majority of teeth were glued into their alveoli. The number of roots on loose teeth was counted, or the alveoli themselves were examined when a tooth was artefactually absent. The presence of supernumerary teeth adjacent to the normal dentition was recorded, as were any persistent deciduous teeth. Attrition/abrasion was assigned to describe the wear of cusp tips. Six fracture types were assigned according to the World Health Organization classification of human dental fractures, as modified for use in carnivores (Verstraete, 2003). Periapical lesions were noted; periapical lesions were considered a bony fenestration or a periosteal reaction overlying the apex of a tooth. Periodontal status was assessed based on an established classification system adapted for use on skulls (Verstraete *et al.*, 1996a,b). Periodontitis stages 2–4 were assigned to the bony lesions indicative of periodontitis; stage 1 was excluded, as it refers to gingivitis, a soft tissue lesion that could not be

**Table 1**  
**Congenital, developmental and acquired abnormalities noted, and inclusion criteria**

<i>Observation</i>	<i>Criteria</i>
Tooth artefactually absent	Jaw fragment missing or tooth absent, but a well-defined, sharp-edged, normally shaped, empty alveolus present; tooth presumed lost during preparation or post-mortem manipulation of the skull.
Tooth absent—presumably acquired	Tooth absent; alveolus or remnant alveolus visible; alveolar bone shows pathological signs (i.e. rounding of the alveolar margin, shallow alveolus, periosteal reaction on alveolar bone, increased vascular foramina).
Tooth absent—presumably congenital	Tooth and alveolus absent; smooth, morphologically normal bone present at the site; no physical space for that tooth to have occupied.
Malformed tooth	Presence of an abnormally shaped crown.
Number of roots	The number of roots inspected directly or inferred from an empty alveolus or from the portion of root(s) visible within the alveolus (if the tooth is glued in place).
Supernumerary tooth	Presence of a supernumerary tooth adjacent to an expected tooth (or alveolus).
Persistent deciduous tooth	A persistent deciduous tooth adjacent to an erupted or unerupted permanent tooth.
Attrition/abrasion	Exposure of dentine on the cuspal tip, with or without tertiary dentine formation.
Enamel fracture	A chip fracture or crack of the enamel only.
Uncomplicated crown fracture	A fracture involving enamel and dentine, but not exposing the pulp.
Complicated crown fracture	A fracture involving enamel and dentine, with pulp exposure.
Uncomplicated crown—root fracture	A fracture involving enamel, dentine and cementum, but not exposing the pulp.
Complicated crown—root fracture	A fracture involving enamel, dentine and cementum, with pulp exposure.
Root fracture	A fracture affecting dentine, cementum and the pulp.
Periapical lesions	Macroscopically visible periapical bone loss, root tip resorption, sinus tract formation originating periapically, or obvious focal periosteal reaction overlying the apex.
Periodontitis stage 2	Evidence of increased vascularity at the alveolar margin (more prominent vascular foramina in, and slightly rougher texture of, the bone of the alveolar margin).
Periodontitis stage 3	Rounding of the alveolar margin; moderate horizontal or vertical bone loss.
Periodontitis stage 4	Widening of the periodontal space; severe horizontal or vertical bone loss; tooth mobile in the alveolus.
Enamel hypoplasia	Irregular pitting, or a band-shaped absence or thinning of the enamel, consistent with the clinical signs of enamel hypoplasia.
Mild TMJ osteoarthritis	Evidence of early periarticular new bone formation/osteophytes with minimal or no subchondral bone change.
Moderate TMJ osteoarthritis	Periarticular new bone formation and/or subchondral bone changes.
Severe TMJ osteoarthritis	All previously described signs are present and more pronounced; subchondral bone lysis present; partial or complete ankylosis may be observed.

assessed. Stage 2 shows increased vascularity (i.e. increased bone porosity) at the alveolar margin. Stage 3 shows rounding of the alveolar margin with >3 mm of vertical or horizontal bone loss. Periodontitis stage 4 shows widening of the alveolar margin with severe vertical or horizontal bone loss and teeth that are unstable in the alveoli or missing secondary to alveolar changes. Enamel changes that would be consistent with the clinical signs of enamel hypoplasia were looked for.

In examining the TMJs, the mandibular head and mandibular fossa of the temporal bone were inspected independently on both the left and right side of the skull. A semiquantitative scoring system (Arzi *et al.*, 2013a,b) for osteoarthritis (OA) was applied to each affected bone; TMJ-OA stages were scored from mild to severe. Joints were scored as having mild OA if there was any evidence of early periarticular new bone formation/osteophytes with minimal or no subchondral bone change, or if there was increased

porosity or irregular texture of the articular surface(s). Joints were scored as having moderate OA if periarticular new bone formation was more pronounced and/or if there was subchondral bone destruction. Joints were scored as having severe OA if there was severe periarticular new bone formation/osteophytes, marked subchondral bone destruction, or if partial or complete ankylosis was observed.

Data from all adult and young adult specimens were pooled according to tooth type and were analyzed with descriptive statistics. Prevalence of lesions was compared with age and sex. Significance was calculated by Fisher's exact test and  $P < 0.05$  was considered significant.

## Results

The collection date of specimens ranged from 1932 to 2014. Of the 107 specimens available, 76 were included in this study; the others were omitted due



to mixed dentition (juvenile status) or excessive ante-mortem or post-mortem trauma preventing the ability to analyse teeth for pathology. Of the 76 included specimens, 20 had only the maxillae available, three had only the mandibles available and 53 were complete walrus skulls, having both the maxillae and mandibles available for review. Of the specimens included in this study, 45 (59.2%) were from male animals, 29 (38.2%) were from female animals and two (2.6%) were from animals of unknown sex. Adult and young adult specimens comprised 58 (76.3%) and 18 (23.7%) of the total included specimens, respectively.

#### Presence of Teeth

The total number of teeth available for examination was 830 (33.6%) out of a theoretical potential maximum of 2,468. Artefactual absence accounted for 457 (18.5%) teeth (i.e. lost during the specimen preparation process); 82 (3.3%) teeth were deemed absent due to acquired tooth loss (i.e. lost during the course of the animal's life) and 1,099 (44.5%) were absent congenitally (Table 2; Fig. 2). Nearly half (47.4%) of the specimens had at least one tooth deemed absent due to acquired loss. The most common locations for acquired tooth loss were the right and left maxillary fourth premolar teeth (25.6% of all cases) and right and left maxillary first molar teeth (20.7% of all cases). Incisor, premolar and molar teeth were frequently absent congenitally: 91.8% of maxillary first incisor teeth, 67.1% of maxillary second incisor teeth, 62.3% of maxillary fourth premolar teeth, 68.5% of maxillary first molar teeth, 95.9% of maxillary second molar teeth, 94.6% of mandibular first incisor teeth, 92.9% of mandibular second incisor teeth, 94.6% of mandibular third incisor teeth, 83.9% of mandibular first molar teeth and 97.3% of mandibular second molar teeth (the remaining tooth types were rarely absent congenitally).

#### Tooth Form

The vast majority of teeth were normal in morphology; only five teeth (0.6% of available teeth) were malformed. A young adult male specimen had an abnormally formed right mandibular fourth premolar tooth (Fig. 3). It is suspected that this abnormal form arose from a supernumerary root; however, it is possible (but less likely) that this tooth represents fusion of the right mandibular fourth premolar tooth with the adjacent first molar tooth (which was deemed absent congenitally in this specimen). An adult male specimen displayed a microdont right maxillary first molar tooth (Fig. 4). Three adult male specimens displayed even smaller teeth, deemed vestigial teeth because they were minimally erupted past the surrounding alveolar bone. One such tooth was a right maxillary second incisor, one was a left maxillary fourth premolar tooth and one was a right mandibular first molar tooth.

#### Number of Roots

All teeth were single-rooted and thus considered normal in this regard, with the exception of the aforementioned right mandibular fourth premolar tooth, which was suspected to have two roots (Fig. 3).

#### Supernumerary Teeth

One young adult male specimen possessed a supernumerary right maxillary third incisor tooth (Fig. 5). No other specimens displayed supernumerary teeth.

#### Persistent Deciduous Teeth

None of the 76 adult or young adult specimens exhibited persistent deciduous teeth. Specimens with physiological mixed dentition were excluded from study.

**Table 2**  
Record of which teeth were present, lost *post mortem* (artefactually absent), lost *ante mortem* (acquired tooth loss) and congenitally absent

	Left										Right									
	I1	I2	I3	C	P1	P2	P3	P4	M1	M2	I1	I2	I3	C	P1	P2	P3	P4	M1	M2
<b>MAXILLA</b>																				
Present	3	9	56	52	61	57	52	10	8	0	2	12	52	46	61	53	51	6	10	0
Artefactual absence	3	11	14	21	12	16	18	9	7	3	2	9	18	26	12	20	19	9	4	3
Acquired tooth loss	1	3	0	0	0	0	1	9	8	0	1	4	0	1	0	0	2	12	9	0
Congenitally absent	66	50	3	0	0	0	2	45	50	70	68	48	3	0	0	0	1	46	50	70
<b>MANDIBLE</b>																				
Present	0	0	1	29		30	29	21	1	0	0	0	0	28		33	31	21	5	0
Artefactual absence	0	0	1	26		25	24	31	5	1	0	0	2	26		23	24	27	4	2
Acquired tooth loss	3	4	1	0		1	3	2	3	0	3	4	1	1		0	1	4	0	0
Congenitally absent	53	52	53	1		0	0	2	47	55	53	52	53	1		0	0	4	47	54

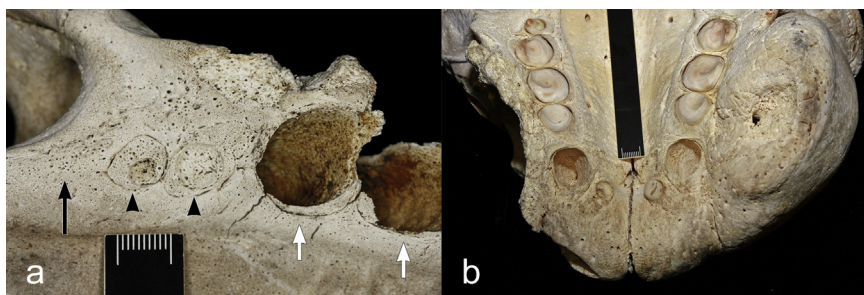


Fig. 2. Types of tooth loss depicted in a young adult male specimen. (a) Artefactual tooth loss (white arrows marking the alveoli of the right maxillary second and third premolar teeth) versus acquired tooth loss (arrowheads marking the remodelling alveoli of the right fourth premolar and first molar teeth) versus congenitally absent tooth (black arrow marking the region of the absent second molar tooth). (b) Relatively severe acquired tooth loss of the right maxillary canine tooth (tusk) versus artefactual loss of the contralateral canine tooth. Bar, 1 cm.

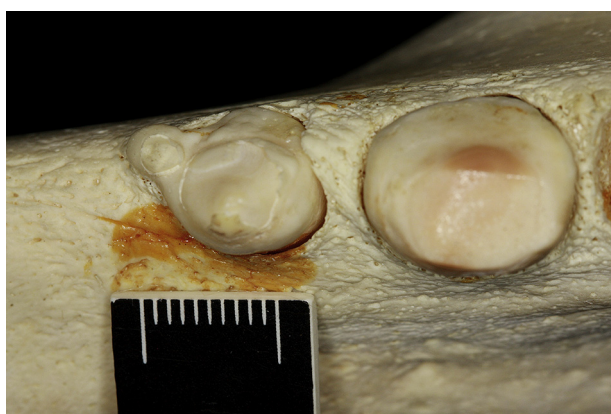

Fig. 3. Abnormally formed right mandibular fourth premolar tooth in a young adult male specimen. Bar, 1 cm.

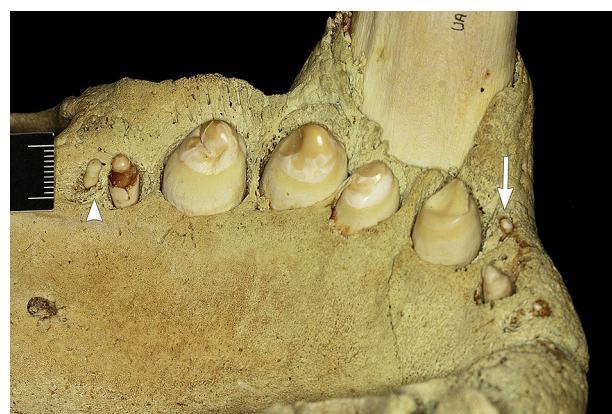

Fig. 5. Supernumerary right maxillary third incisor tooth in a young adult male specimen (arrow). This specimen has more complete dentition than the majority of specimens, having all three right maxillary incisor teeth, the right maxillary canine tooth, all four right maxillary premolar teeth and the right maxillary first molar tooth (arrowhead). Bar, 1 cm.

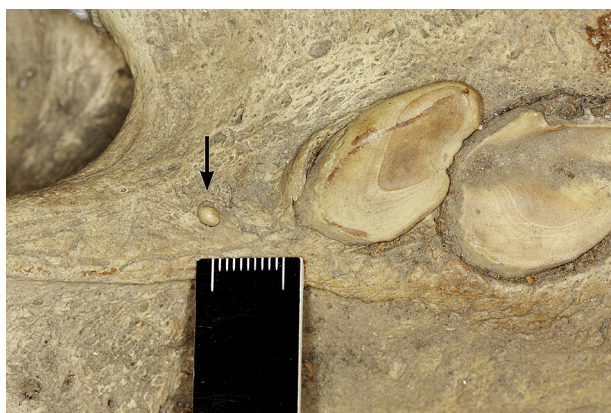

Fig. 4. Microdont right maxillary first molar tooth in an adult male specimen (arrow). Compare the size of this tooth with the maxillary first molar tooth in Fig. 5 (arrowhead). Bar, 1 cm.

#### *Attrition/Abrasion*

The majority of teeth (85.5%) displayed attrition/abrasion. The pattern of wear often resulted in the development of points on the buccal aspect of the

maxillary premolar teeth (Fig. 6). Of the adult and young adult specimens, 90.8% showed some degree of attrition/abrasion on at least one tooth. Only two adult specimens (with only mandibles available for study) were not affected by attrition/abrasion, while five young adult specimens were not affected by attrition/abrasion; thus, almost all adult specimens (96.6%) were affected, while significantly fewer young adults (72.2%) were affected ( $P = 0.0070$ ). There was no significant difference between the proportion of males ( $n = 43$ , 95.5%) and females ( $n = 24$ , 82.8%) affected by attrition/abrasion ( $P = 0.1033$ ). Nearly half of all specimens ( $n = 37$ , 48.7%) displayed attrition/abrasion of all teeth present, with an additional 21 specimens (27.6%) displaying attrition/abrasion of all teeth present aside from the maxillary canine teeth.



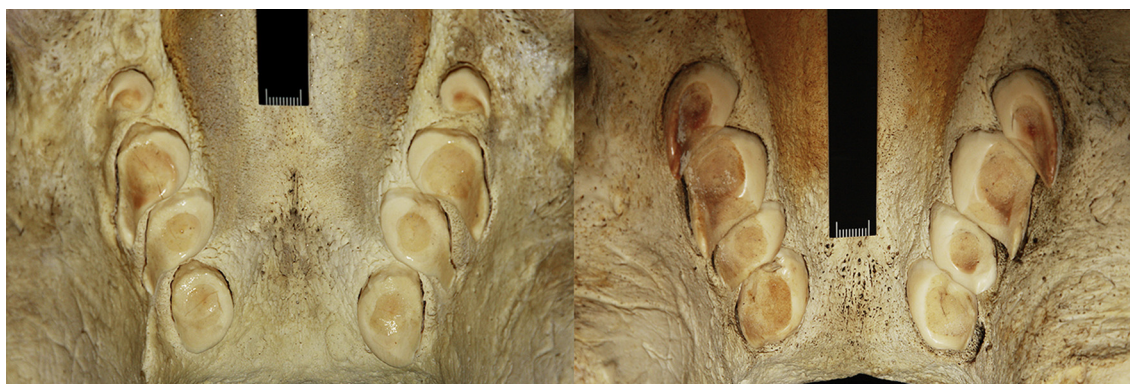

Fig. 6. Attrition/abrasion of the maxillary teeth in two adult male specimens, demonstrating a pattern of buccal point development. Bar, 1 cm.

### *Tooth Fractures*

Dental fractures were noted in eight walruses, affecting 10.5% of specimens and 1.3% of the total number of teeth present ( $n = 11$ ). All walruses suffering from dental fractures were of adult age, while no young adult specimens had fractured teeth; however, this finding is not significant ( $P = 0.1863$ ), likely due to the small sample size of individuals with dental fractures. Of individuals with fractured teeth, the majority were males (seven males [15.6% of males] versus one female [3.5% of females]), but again, this finding was not significant ( $P = 0.1378$ ). Only two fracture types were represented in the pooled data: complicated crown fractures (45.5% of fractures) and complicated crown–root fractures (54.5% of fractures). The maxillary canine teeth were fractured most often, accounting for 72.7% of all fractures. The remaining fractured teeth were a mandibular canine tooth and mandibular second premolar teeth. One specimen had complicated crown–root fractures of both maxillary canine teeth; one specimen had a complicated crown–root fracture of the right maxillary canine tooth and right mandibular canine tooth; one specimen had bilateral complicated crown–root fractures of the mandibular second premolar teeth; the other five affected specimens displayed one fractured maxillary canine tooth each.

### *Periapical Disease*

Three specimens (3.9%), all adult males, displayed overt periapical disease. One specimen with a complicated crown–root fracture of the left maxillary canine tooth had fenestration of that alveolus (Figs. 7a, b). Another specimen had periapical bone loss and alveolar dehiscence associated with a complicated crown fracture of the right maxillary canine tooth (Fig. 7c). The third specimen had a periapical fenestra-

tion associated with an acquired missing left maxillary fourth premolar tooth.

### *Alveolar Bony Changes Consistent with Periodontitis*

The majority (99.2%) of alveoli, either with or without teeth, did not have bony changes indicative of periodontitis. Only five specimens (6.6%) were affected by periodontitis, all of which were adult males. Between these five specimens, seven alveoli (0.8%) were affected by periodontitis. One specimen displayed stage 2 periodontitis of the right mandibular second premolar tooth. A different specimen displayed stage 3 periodontitis of the left maxillary third incisor tooth and first premolar tooth. Another specimen showed stage 3 periodontitis of the right mandibular second premolar tooth and stage 4 periodontitis of the right mandibular third premolar tooth. The specimen that suffered from a right maxillary canine tooth complicated crown fracture and associated periapical disease additionally displayed stage 4 periodontitis of this alveolus (Fig. 7c). The specimen that suffered from acquired tooth loss of the left maxillary fourth premolar tooth and associated periapical disease also displayed stage 4 periodontitis of this alveolus.

### *Enamel Hypoplasia*

None of the teeth examined was affected by enamel hypoplasia.

### *Temporomandibular Joint Pathology*

Lesions consistent with TMJ-OA were found in 46 specimens, accounting for 60.5% of the total number of walruses. In these 46 specimens, a total of 139 different lesion sites were observed (affecting a combination of the right mandibular head and/or left mandibular head and/or right mandibular fossa of

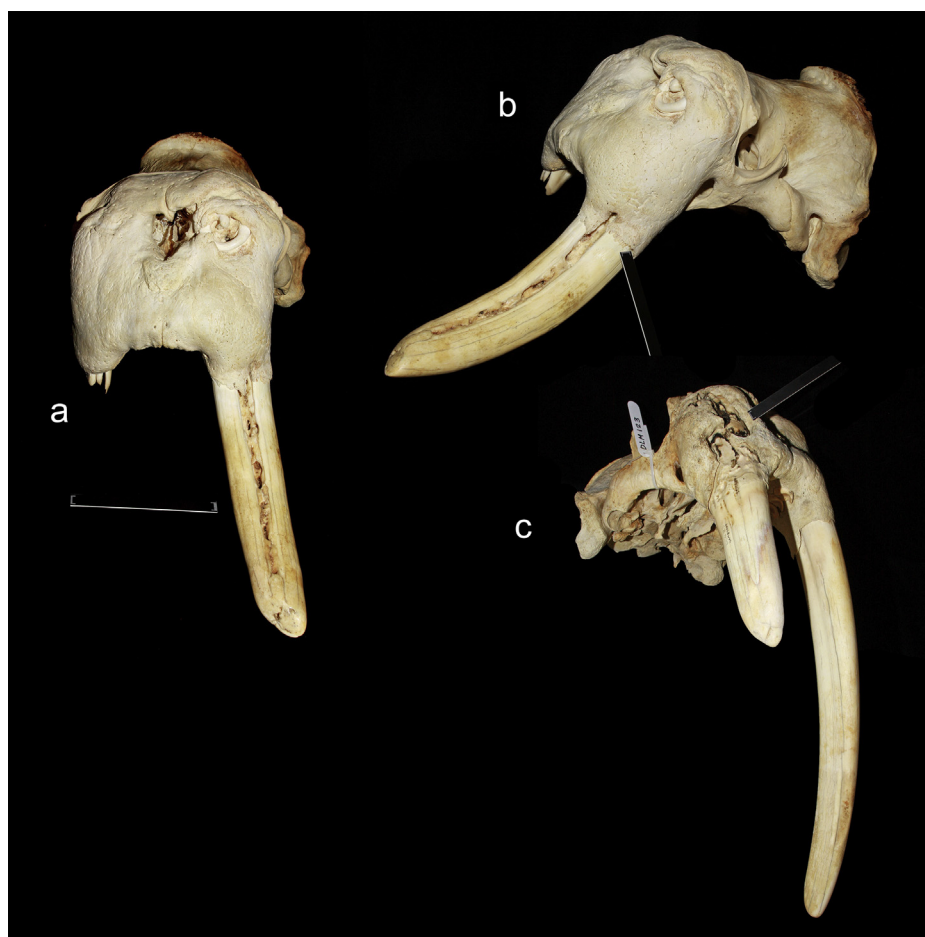


Fig. 7. Complicated crown–root fractures of the right and left maxillary canine teeth of an adult male specimen (a, b) and a complicated crown fracture of the right maxillary canine tooth in an adult male specimen (c). Note the associated periapical lesions of the left (a, b) and right (c) maxillary canine teeth. End of the scale bar, 1 cm.

the temporal bone and/or left mandibular fossa of the temporal bone). The most common TMJ-OA changes were the presence of subchondral bone defects and increased bone porosity, suggestive of increased vasculature due to inflammation. Overall, mild TMJ-OA was most common, accounting for 54.7% of all articular surfaces affected by TMJ-OA, followed by moderate TMJ-OA (30.2%) and severe TMJ-OA (15.1%). There were 26 specimens (out of the 53 complete skulls with both maxillae and mandibles available, 49.1%) that displayed some degree of TMJ-OA on all four articular surfaces. When present, lesions were typically generalized in location, affecting the entire joint surface equally. Four specimens showed severe, general OA of both mandibular heads, while the fossae were affected by mild or moderate OA. There were three specimens with severe, generalized OA of all articular surfaces (Fig. 8). Adults were significantly more likely to exhibit TMJ-OA than young adults (75.9% of adults were affected [ $n = 44$ ] versus 11.1% of young adults [ $n = 2$ ],  $P < 0.0001$ ). Significantly more males

than females were affected by TMJ-OA (86.6% of males were affected [ $n = 39$ ] versus 17.2% of females [ $n = 5$ ],  $P < 0.0001$ ).

#### Other Findings

There were two specimens, both adult females, that displayed linguverted maxillary canine teeth to such a degree that the tips of the tusk crowns converged and essentially touched (Fig. 9). In the previously described adult male specimen suffering from bilateral complicated crown–root fractures of the maxillary canine teeth (Figs. 7a, b), there was a lesion visible within the periapical fenestration consisting of contorted dental substance.

## Discussion

Examination of this collection of specimens enabled characterization of the nature and prevalence of dental pathology and TMJ lesions in the walrus.



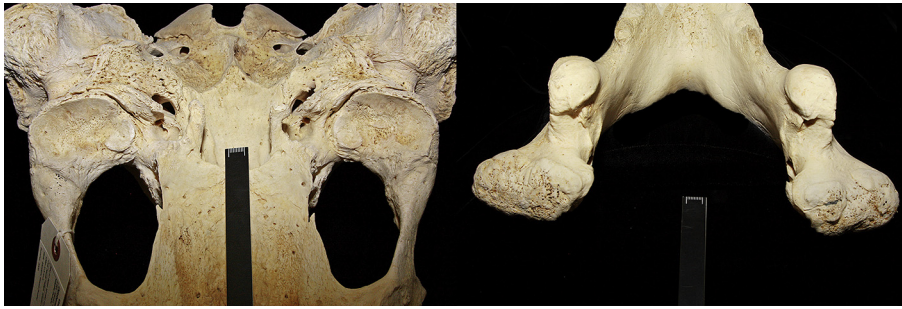

Fig. 8. Severe, generalized TMJ-OA on all articular surfaces in an adult male specimen. Bar, 1 cm.



Fig. 9. Linguoverted maxillary canine teeth in an adult female specimen such that the tips of the canine crowns are convergent. Bar, 1 cm.

Some skulls and teeth possessed defects clearly owing to post-mortem trauma or preparation artefacts; however, these defects were discounted and did not impinge on the evaluation of true pathology. Investigating lesion variability over the 82-year collection period was problematic because specimen procurement was erratic, with inconsistent numbers and ages of specimens collected over time. Therefore, no obvious trends correlating to chronology could be identified.

Determining a universal dental formula for the adult walrus has proven problematic, as the presence and congenital absence of teeth varies between individuals. In contrast to other marine mammal species, whose prevalence of congenitally absent teeth ranges from 0.03% to 2.8% (Abbott and Verstraete, 2005; Winer *et al.*, 2013; Sinai *et al.*, 2014; Alderink *et al.*, 2015a,b), congenital absence of teeth is a common occurrence in the walrus. Fay (1982) noted that the following teeth were present in <50% of adult wal-

ruses: the maxillary first and second incisor teeth; the maxillary fourth premolar tooth; the maxillary first and second molar teeth; the mandibular first, second and third incisor teeth; and the mandibular first and second molar teeth. Fay pooled his data from the left and right dental arches and recorded a tooth as being present if it was either present unilaterally or bilaterally, while we counted teeth as individuals; therefore, this study reports a higher incidence of congenitally absent teeth and our data sets cannot be compared directly. For the teeth noted to be absent >50% of the time by Fay, our prevalence of congenital absence for these same teeth ranged from 62.3% to 97.3%. Therefore, the theoretical complete dental formula is I 3/3, C 1/1, P 4/3, M 2/2, while the statistically most probable dental formula is I 1/0, C 1/1, P 3/3, M 0/0, which is in accordance with the findings of Fay (1982). None of the specimens in this study had a full complement of theoretically possible teeth.

Aside from congenitally absent teeth, congenital and developmental lesions were infrequent in this sample of walruses. Across the five marine mammal species studied previously using the same lesion scoring criteria, as well as in the present study, abnormal tooth form was rare, affecting <1% of the total number of teeth in each species (Abbott and Verstraete, 2005; Winer *et al.*, 2013; Sinai *et al.*, 2014; Alderink *et al.*, 2015a,b). Remarkably few teeth (0.04%) had an abnormal number of roots; this finding is of a similar magnitude as the low prevalence of aberrantly rooted teeth discovered in the southern sea otter (0.02%) (Winer *et al.*, 2013). Equally rare were supernumerary teeth, with the same prevalence of 0.04%; this differs from the 1.3% supernumerary teeth encountered in the California sea lion (Sinai *et al.*, 2014) and the 1.4% found in the northern elephant seal (Abbott and Verstraete, 2005). None of the walrus specimens possessed persistent deciduous teeth or were affected by enamel hypoplasia.

Certain acquired lesions, such as acquired tooth loss, dental fractures, periapical disease and periodontitis, were encountered rarely. While acquired tooth loss

was relatively infrequent, affecting only 3.3% of teeth, it was more prevalent than is documented in other marine mammal species: 0.7% of teeth in the northern elephant seal (Abbott and Verstraete, 2005), 0.6% of teeth in the southern sea otter (Winer *et al.*, 2013), 0.4% of teeth in the California sea lion (Sinai *et al.*, 2014), 0.8% of teeth in the northern fur seal (Aalderink *et al.*, 2015a) and 2.3% of teeth in the eastern Pacific harbour seal (Aalderink *et al.*, 2015b).

Dental fractures were also relatively rare (1.3%), about as common as in the northern elephant seal (1.2%) (Abbott and Verstraete, 2005) and northern fur seal (1.1%) (Aalderink *et al.*, 2015a). Nearly three-quarters of all fractures affected the maxillary canine teeth, which could potentially have devastating consequences, as the tusks are utilized for myriad functions: for breaking through ice and mounting ice floes, for defence against predators, for threat displays and intraspecific aggression, for communicating and for social displays (Miller, 1975; Fay, 1982; MacCracken and Benter, 2015). Therefore, when tusk fractures occur, they have, potentially, a major impact on morbidity and mortality, as their function is altered and the individual would suffer from discomfort or pain. More males than females were affected by tusk fractures; however, this trend was not significant ( $P = 0.2345$ ), likely due to the small sample size of individuals with tusk fractures. This trend may be due to differential use of these teeth by males, as breeding males are known to use their tusks as weapons when defending breeding display positions near groups of oestrous females (MacCracken and Benter, 2015). Fay (1982) also noted that tusk fractures tended to occur most often in mature males, possibly because females avoid haul outs on rocky shores and engage in less forceful fights. Out of 79 females studied by Fay (1982), two showed unilateral tusk fractures (2.5%); the present study found a similar female tusk fracture rate of 3.4%.

Periapical lesions were observed in only 3.9% of the specimen population, affecting 0.1% of teeth. Periapical lesions typically result from pulp exposure and subsequent pulp necrosis. As lesions are only obvious on skull specimens when severe, it is probable that this pathology was underdetected; radiographical examination would have likely revealed smaller, subtler lesions beyond those noted during macroscopic examination.

Alveolar bony changes consistent with periodontitis were observed in the minority of specimens (6.6%). Diagnosis of periodontal lesions from dry skulls is fundamentally flawed because soft tissue lesions, crucial in pathogenesis, are unavailable for study. However, an increase in vascular foramina and alveolar bone loss are signs of periodontal disease.

In our sample, only adult specimens displayed signs of periodontal disease; this is in contrast to the periodontitis encountered in young adult and juvenile specimens of the northern elephant seal, the southern sea otter, the Californian sea lion, the eastern Pacific harbour seal and the northern fur seal (Abbott and Verstraete, 2005; Winer *et al.*, 2013; Sinai *et al.*, 2014; Aalderink *et al.*, 2015a,b).

Other acquired lesions, such as attrition/abrasion and TMJ-OA, were often encountered in this sample of walrus. Attrition/abrasion was the most common lesion encountered, affecting 90.8% of all adult and young adult specimens and 85.5% of their teeth. Of the marine mammal species studied previously, the walrus has the highest prevalence of teeth worn down by attrition and abrasion (85.5%), followed by the southern sea otter (52%, Winer *et al.*, 2013), the northern elephant seal (43.3%, Abbott and Verstraete, 2005) and the California sea lion (42.4%, Sinai *et al.*, 2014). The walrus is known to swallow its soft-bodied prey whole, with no indication of mastication (Fay, 1982). Similarly, the teeth of the northern elephant seal are seldom used in mastication, as this pinniped also swallows its sustenance intact (Antonelis *et al.*, 1994). In contrast, the high incidence of attrition/abrasion in the southern sea otter may be ascribed to its prey and chewing habits. Sea otters feed on a diverse diet, but all sea otters appear to include hard foods in their diets (Estes *et al.*, 2003); the majority of shelled prey is chewed (Kenyon, 1969). The California sea lion's excessive tooth wear may be attributable to a combination of abrasion against food items in addition to acid demineralization caused by the feeding habit of regurgitating food to expel indigestible spines and bony structures from prey (Labrada-Martagon *et al.*, 2007). It may be hypothesized that the marked wear of both walrus and northern elephant seal teeth is secondary to abrasion of sand particles that enter the oral cavity while prey is procured from the ocean floor. This theory was proposed by Fay *et al.* (1977), who noted sand and ocean floor sediment embedded within the dentine and cementum of walrus teeth, as well as sand particles within the oral cavity and digestive tract of these specimens.

Lesions consistent with TMJ-OA were observed in 60.5% of the total number of walrus specimens. A previous study on TMJ-OA in the California sea lion (Arzi *et al.*, 2015) found that a similar proportion (63.5%) of those animals were affected, while fewer southern sea otters (4.1%), eastern Pacific harbour seals (34.5%) and northern fur seals (20%) are affected (Winer *et al.*, 2013; Aalderink *et al.*, 2015a,b). The reason for TMJ pathology across pinniped species, and in the walrus specifically,

remains unknown, especially considering that walruses do not masticate their prey (based on stomach contents studies). Further studies characterizing the TMJ of marine mammals and documenting potential clinical consequences of TMJ degeneration are needed.

Attrition/abrasion and TMJ-OA were significantly more prevalent in adult specimens than in young adult specimens, as expected. With advancing age there is increased exposure to inciting causes of acquired dental pathology and increased likelihood of chronic lesions developing (Winer *et al.*, 2013). Additionally, TMJ-OA was significantly more prevalent in male specimens than females ( $P < 0.0001$ ). While the aetiology and significance of this sex difference are unknown, it may be hypothesized that males utilize their teeth and jaws more aggressively as weapons, to defend breeding display positions near groups of females in oestrous (MacCracken and Benter, 2015). In using their tusks in this way, males may be more prone to dental fractures and may put more stress and strain on their TMJs.

A limitation of this study is that only hard tissues were available for macroscopic examination, which could lead to underdiagnosis of pathologies such as periodontal disease (i.e. subtle periapical lesions and gingivitis could not be detected) or overdiagnosis, as at times it can be difficult to differentiate true pathology from artefacts occurring secondary to specimen preparation. It is important to note, given the high prevalence of teeth deemed congenitally absent, that the differentiation between congenitally absent teeth versus acquired tooth loss can be challenging. For example, if a tooth was lost many years prior to death, the vacated alveolus may have had enough time to completely remodel to the point that it appears a tooth was never there at all. Therefore, the true prevalence of congenitally absent teeth may be lower while the true prevalence of acquired tooth loss may be higher. However, given the fact that the occurrence of congenitally absent teeth reported here supports and even surpasses the occurrence recorded in previous studies (Fay, 1982), the authors are confident in the reported prevalence of congenitally absent teeth and acquired tooth loss.

In conclusion, a diversity of dental lesions and abnormalities was discovered in the present study. The prevalence of most lesions was relatively low, but other lesions, including congenitally absent teeth, attrition/abrasion and TMJ-OA, were encountered frequently. Animals with pronounced periapical disease, substantial tusk fractures and advanced TMJ-OA likely suffered morbidity and possibly mortality secondary to these lesions, as these conditions are known to be painful and could lead to discomfort,

pain, infection and/or decreased food intake and defence. Understanding the dental pathology of walruses may aid in the development of good husbandry practices for these animals when in captivity (Sinai *et al.*, 2014). Documenting the prevalence of the various dental lesions present in the walrus contributes to a better understanding of their overall health and strengthens the foundation for advancing the understanding of dental diseases in this species.

### Acknowledgments

The authors thank L. Olsen and A. Gunderson of the Department of Mammalogy, Museum of the North, University of Alaska, Fairbanks, for making its *Odobenus* skull collection available for this study, and J. Doval for assisting with the illustrations. This research was funded by Academic Senate Research Grants and Faculty Discretionary Funds of F. J. M. Verstraete and B. Arzi, University of California, Davis, and by crowdfunding through <https://experiment.com>. The funding agencies had no role in the study design, in the collection, analysis and interpretation of data, in the writing of the manuscript or in the decision to submit the manuscript for publication.

### References

- Aalderink MT, Nguyen HP, Kass PH, Arzi B, Verstraete FJM (2015a) Dental and temporomandibular joint pathology of the northern fur seal (*Callorhinus ursinus*). *Journal of Comparative Pathology*, **152**, 325–334.
- Aalderink MT, Nguyen HP, Kass PH, Arzi B, Verstraete FJM (2015b) Dental and temporomandibular joint pathology of the Eastern Pacific harbour seal (*Phoca vitulina richardii*). *Journal of Comparative Pathology*, **152**, 335–344.
- Abbott C, Verstraete FJM (2005) The dental pathology of northern elephant seals (*Mirounga angustirostris*). *Journal of Comparative Pathology*, **132**, 169–178.
- Antonelis GA, Lowry MS, Fiscus CH, Stewart BS, DeLong RL (1994) Diet of the northern elephant seal. In: *Elephant Seals: Population Ecology, Behavior and Physiology*, BJ Le Boeuf, RM Laws, Eds., University of California Press, Berkeley, pp. 211–223.
- Arzi B, Cissell DD, Verstraete FJ, Kass PH, Duraine GD *et al.* (2013a) Computed tomographic findings in dogs and cats with temporomandibular joint disorders: 58 cases (2006–2011). *Journal of the American Veterinary Medical Association*, **242**, 69–75.
- Arzi B, Leale DM, Sinai NL, Kass PH, Lin A *et al.* (2015) The temporomandibular joint of California sea lions (*Zalophus californianus*): part 2 – osteoarthritic changes. *Archives of Oral Biology*, **60**, 216–222.
- Arzi B, Winer JN, Kass PH, Verstraete FJM (2013b) Osteoarthritis of the temporomandibular joint in southern sea otters (*Enhydra lutris nereis*). *Journal of Comparative Pathology*, **149**, 486–494.



- Cowan DF (2002) Pathology. In: *Encyclopedia of Marine Mammals*, WF Perrin, B Wursig, JGM Thewissen, Eds., Academic Press, San Diego, pp. 883–890.
- Donaldson GM, Chapdelaine G, Andrews JD (1995) Predation of thick-billed murre, *Uria lomvia*, at two breeding colonies of polar bears, *Ursus maritimus*, and walruses, *Odobenus rosmarus*. *Canadian Field Naturalist*, **109**, 112–114.
- Estes JA, Hatfield BB, Ralls K, Ames J (2003) Causes of mortality in California sea otters during periods of population growth and decline. *Marine Mammal Science*, **19**, 198–216.
- Fay FH (1955) *The Pacific Walrus (Odobenus rosmarus divergens): Spatial Ecology, Life History, and Population*. PhD Thesis, University of British Columbia.
- Fay FH (1982) *Ecology and Biology of the Pacific Walrus, Odobenus rosmarus divergens Illiger*. United States Department of the Interior, Fish and Wildlife Service, North American Fauna, pp. 1–279.
- Fay FH, Burns JJ (1988) Maximal feeding depth of walruses. *Arctic*, **41**, 239–240.
- Fay FH, Feder HM, Stoker SW (1977) *An Estimate of the Impact of the Pacific Walrus Population on its Food Resources in the Bering Sea*. PB-73-505. US National Technical Information Service, Springfield.
- Freuchen P (1935) Mammals, part II: Field notes and biological observations. In: *Report of the Fifth Thule Expedition 1921–1924*, Nordisk-Forlag, Copenhagen, pp. 68–278.
- Gjertz I (1990) Walrus predation of seabirds. *Polar Record*, **26**, 317.
- Gulland FM (1999) Stranded seals: important sentinels. *Journal of the American Veterinary Medical Association*, **214**, 1191–1192.
- Hillson S (2005) Tooth form in mammals: order Pinnipedia. In: *Teeth*, 2nd Edit., Cambridge University Press, Cambridge, pp. 67–69.
- Houssaye A (2009) ‘Pachyostosis’ in aquatic amniotes: a review. *Integrative Zoology*, **4**, 325–340.
- Jay CV, Marcot BG, Douglas DC (2011) Projected status of the Pacific walrus (*Odobenus rosmarus divergens*) in the twenty-first century. *Polar Biology*, **34**, 1065–1084.
- Jefferson TA, Webber MA, Pitman RL (2008) Pinniped species accounts. In: *Marine Mammals of the World: A Comprehensive Guide to Their Identification*, Elsevier, Amsterdam, pp. 306–445.
- Kenyon KW (1969) *The Sea Otter in the Eastern Pacific Ocean*. North American Fauna, US Bureau of Sport, Fisheries and Wildlife, Washington DC, pp. 326–336.
- Kryukova NV (2012) Dentition in Pacific walrus (*Odobenus rosmarus divergens*) calves of the year. *Biology Bulletin*, **39**, 1385–1394.
- Labrada-Martagon V, Auriolos-Gamboa D, Castro-Gonzalez MI (2007) Relation of dental wear to the concentrations of essential minerals in teeth of the California sea lion *Zalophus californianus*. *Biological Trace Element Research*, **115**, 107–126.
- Lowry LF, Fay FH (1984) Seal eating by walruses in the Bearing and Chukchi Seas. *Polar Biology*, **3**, 11–18.
- MacCracken JG, Benter RB (2015) Trend in Pacific walrus (*Odobenus rosmarus divergens*) tusk asymmetry, 1990–2014. *Marine Mammal Science*, **32**, 588–601.
- Miller EH (1975) Walrus ethology. 1. The social role of tusks and applications of multidimensional scaling. *Canadian Journal of Zoology*, **53**, 590–613.
- de Ricqlès A, de Buffrénil V (2001) Bone histology, heterochronies and the return of tetrapods to life in water: where are we? In: *Secondary Adaptation of Tetrapods to Life in Water*, JM Mazin, V de Buffrénil, Eds., Verlag, München, pp. 289–310.
- Sheffield G, Fay FH, Feder H, Kelly BP (2001) Laboratory digestion of prey and interpretation of walrus stomach contents. *Marine Mammal Science*, **17**, 310–330.
- Sheffield G, Grebmeier JM (2009) Pacific walrus (*Odobenus rosmarus divergens*): differential prey digestion and diet. *Marine Mammal Science*, **25**, 761–777.
- Sinai NL, Dadaian RH, Kass PH, Verstraete FJM (2014) Dental pathology of the California sea lion (*Zalophus californianus*). *Journal of Comparative Pathology*, **151**, 113–121.
- Speckman S, Chernook VI, Burn DM, Udevitz MS, Kochnev AA *et al.* (2011) Results and evaluation of a survey to estimate Pacific walrus population size, 2006. *Marine Mammal Science*, **27**, 514–553.
- Verstraete FJM (2003) Dental pathology and microbiology. In: *Textbook of Small Animal Surgery*, Vol. 2, DH Slatter, Ed., WB Saunders, Philadelphia, pp. 2638–2651.
- Verstraete FJM, van Aarde RJ, Nieuwoudt BA, Mauer E, Kass PH (1996a) The dental pathology of feral cats on Marion Island, part I: congenital, developmental and traumatic abnormalities. *Journal of Comparative Pathology*, **115**, 265–282.
- Verstraete FJM, van Aarde RJ, Nieuwoudt BA, Mauer E, Kass PH (1996b) The dental pathology of feral cats on Marion Island, part II: periodontitis, external odontoclastic resorption lesions and mandibular thickening. *Journal of Comparative Pathology*, **115**, 283–297.
- Vibe C (1950) The marine mammals and the marine fauna in the Thule district (northwest Greenland) with observations on ice conditions in 1939–41. *Meddelelser om Grønland*, **150**, 1–115.
- Winer JN, Liong SM, Verstraete FJM (2013) The dental pathology of southern sea otters (*Enhydra lutris nereis*). *Journal of Comparative Pathology*, **149**, 346–355.

[ Received, May 11th, 2016 ]  
 [ Accepted, July 3rd, 2016 ]